

A case of Hutch diverticulum leading to non-functioning kidney due to vesico-ureteric reflux.

Abstract: Bladder diverticulum is caused by herniation of the urothelium through the muscular layer of the bladder wall, being formed by mucosa, lamina propria, few muscular fibres and adventitia. Bladder diverticula are classified as congenital or acquired. Congenital ones usually appear in young ages with a maximum incidence before 10 years and are usually unique, almost exclusively in males, located posteromedially to the ureteral ostium and resulting from the weakness of the bladder wall in this portion. Acquired ones generally are due to high intra-vesical pressure caused by infra-vesical obstruction or detrusor-sphincter dyssynergia. More rarely are due to wall debility after bladder surgery. Often develop in males after sixth decade, in about 12% of patients with infra-vesical obstruction.^{1,2} Usually multiple and associated with important trabeculation of the bladder wall. If the ureteral ostium is included in the bladder diverticulum, it is called Hutch diverticulum, which is a rare entity, typically in young ages, with few cases identified in the adult. We hereby present a case of a patient with acquired hutch diverticulum leading to non-functioning kidney due to vesico-ureteric reflux.

Keywords: Hutch diverticulum, non-functioning kidney, paraureteral diverticulum, vesico-ureteric reflux.

Case report:

A 60-year-old male patient presented to the outpatient Urology department of a tertiary care centre with complaints of burning sensation while passing urine intermittently over the past 8 months associated with straining while passing urine. Patient had taken multiple courses of oral antibiotics as prescribed by his primary physician and his complaints resolved. However, he suffered recurrent episodes and so he decided to consult a urologist for his complaints. Patient was evaluated in the urology outpatient department. Clinical examination revealed abdominal midline scar of previous exploratory laparotomy for peptic ulcer perforation. Bladder was not percussible. Local examination of genitalia revealed circumcised penis with normal penile shaft and glans; bilateral testis was normal along with a normal perineum. Per rectal examination revealed a grade 2 enlarged lateral lobes of prostate with firm consistency. Patient was then evaluated using an ultrasound of the kidney, ureter and bladder which revealed right sided pelvicalyceal fullness with mild hydroureter throughout its entire extent with thickened bladder wall (thickness-7.2 mm) and a prostate of size-62.2 gms with post void residue of 110 ml. His blood investigations revealed normal serum creatinine-0.9 mg/dl. He was then further evaluated using Computerised Topography Urography (CT urography) to determine the cause of the right sided obstruction and further evaluate the urinary anatomy. CT Urography revealed shrunken small right kidney with gross hydronephrosis with minimal excretion associated with gross hydroureter and dilated right ureter seen inserting into the bladder diverticulum (Hutch diverticulum with opening of size-2 cm and dimensions being 3cm *4.2 cm *5.8 cm). Left side kidney and ureter were normal with prompt excretion of contrast indicating good left sided renal function. Prostate- 52 cc.

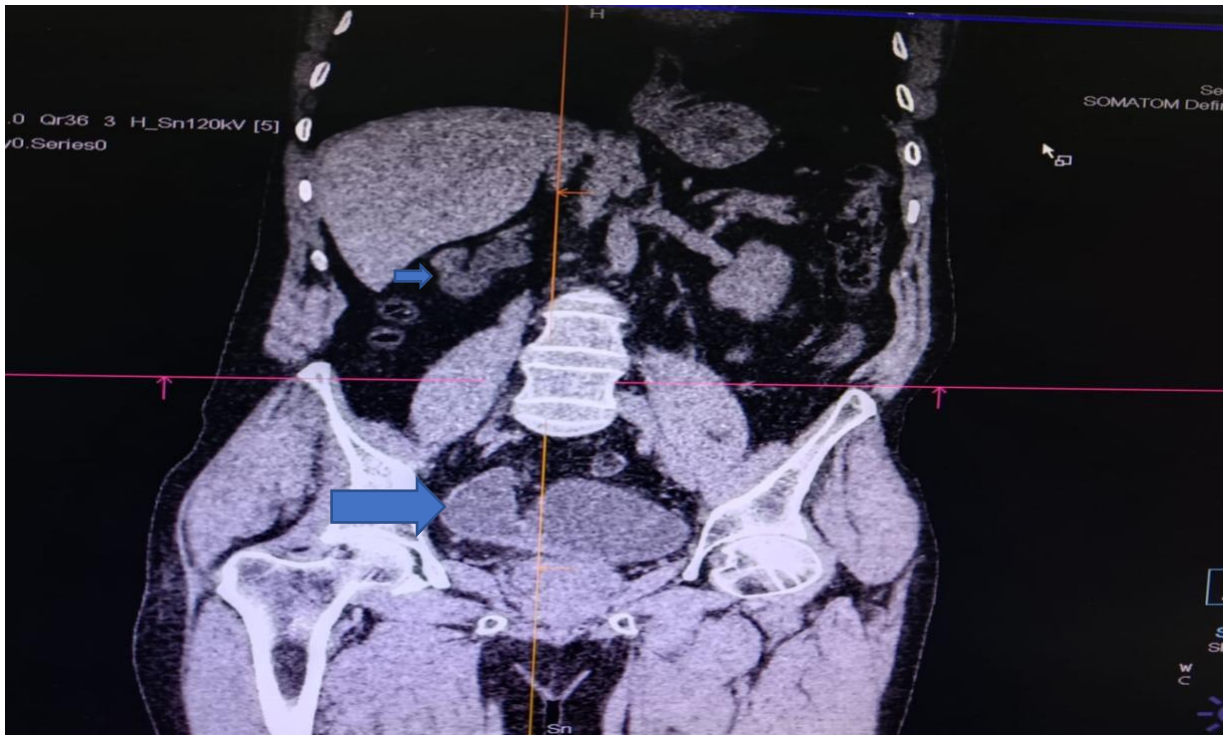


Figure 01- Coronal section of CT urography (Plain film) showing shrunken right kidney (small arrow) and right hutch bladder diverticulum (long arrow)

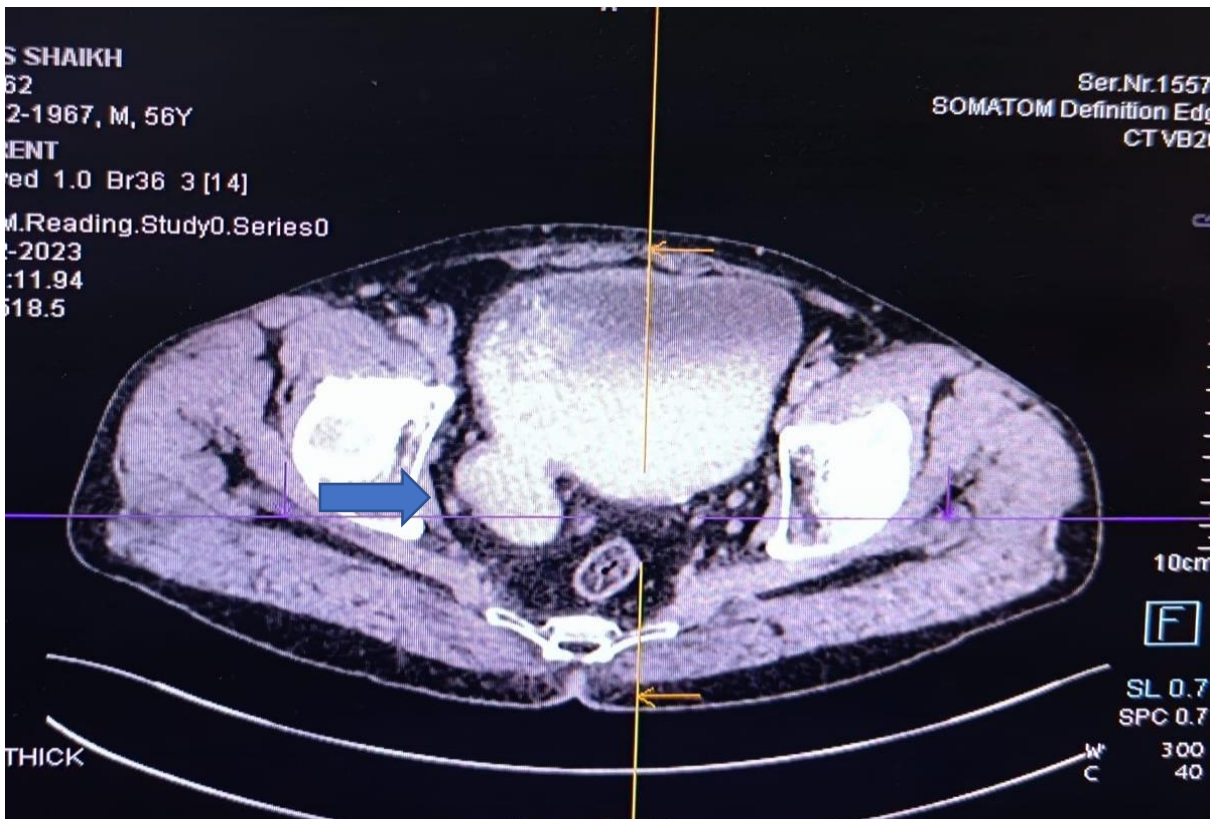


Figure 02- Axial section of CT urography (Excretory phase) showing right ureter draining into right hutch diverticulum.

He then underwent nuclear DTPA scan with F-O protocol to confirm the absence of function of the right sided kidney. Right kidney showed a GFR of 4 ml/min while the left kidney had a GFR of 50 ml/min. There was no peak observed in the graph plotted for right kidney. Thus, DTPA scan confirmed right sided non-functioning kidney.

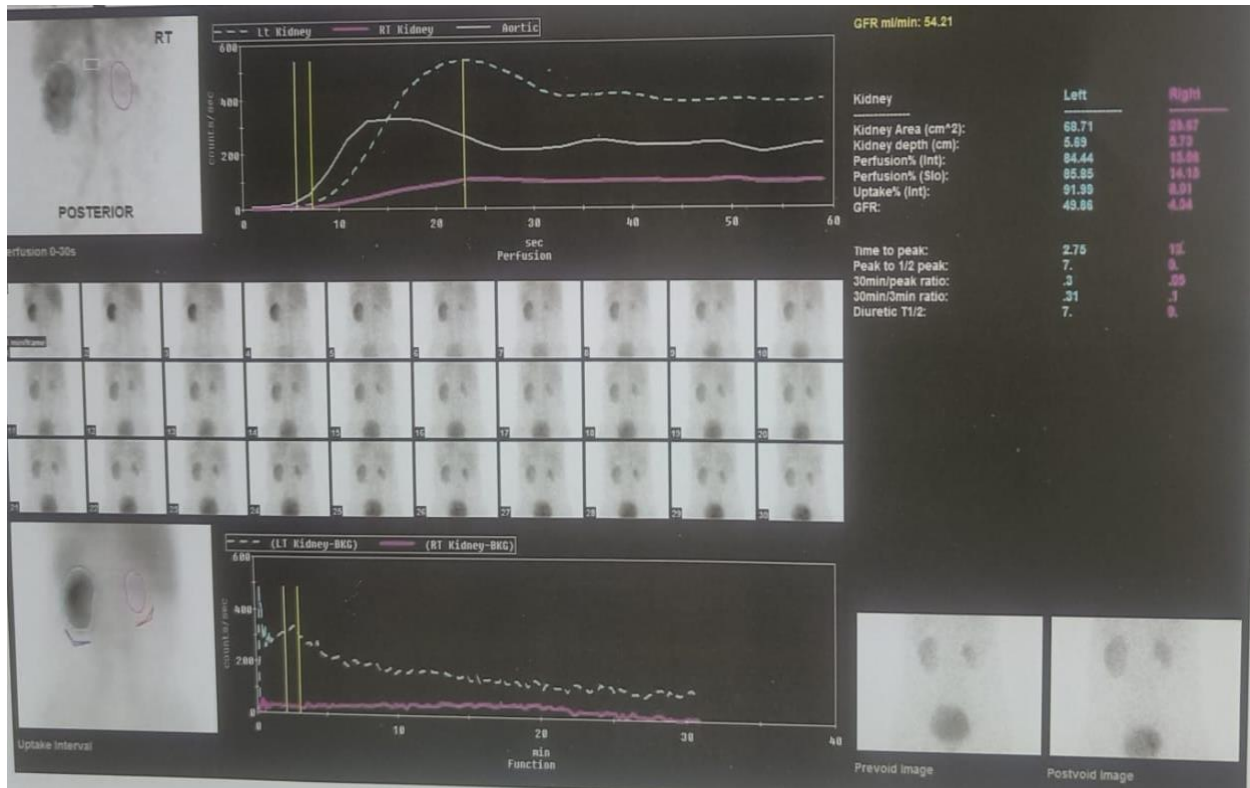


Figure 03- DTPA nuclear scan showing non-functioning right kidney and normal left kidney.

Patient's uroflowmetry pattern showing decreased peak suggestive of straining pattern with average flow rate of 18 ml/sec. Voiding cystourethrogram showed right sided Grade 3 vesico-ureteric reflux and right sided paraureteral hutch diverticulum. Cystourethroscopy revealed - circumcised penis, Meatus and anterior urethral calibre was narrow and could admit 19 F sheath with some difficulty; prostate- grade 2 enlarged lateral lobes and median lobe was normal; Bladder neck was normal; Bladder wall showed multiple trabeculation; Left ureteric orifice was normal; Right ureteric orifice was not visualised; instead evidence of right sided hutch diverticulum with mouth of the diverticulum being 2 cm wide and no evidence of any growth in the diverticulum or the rest of the bladder wall; bladder capacity was 450 ml.

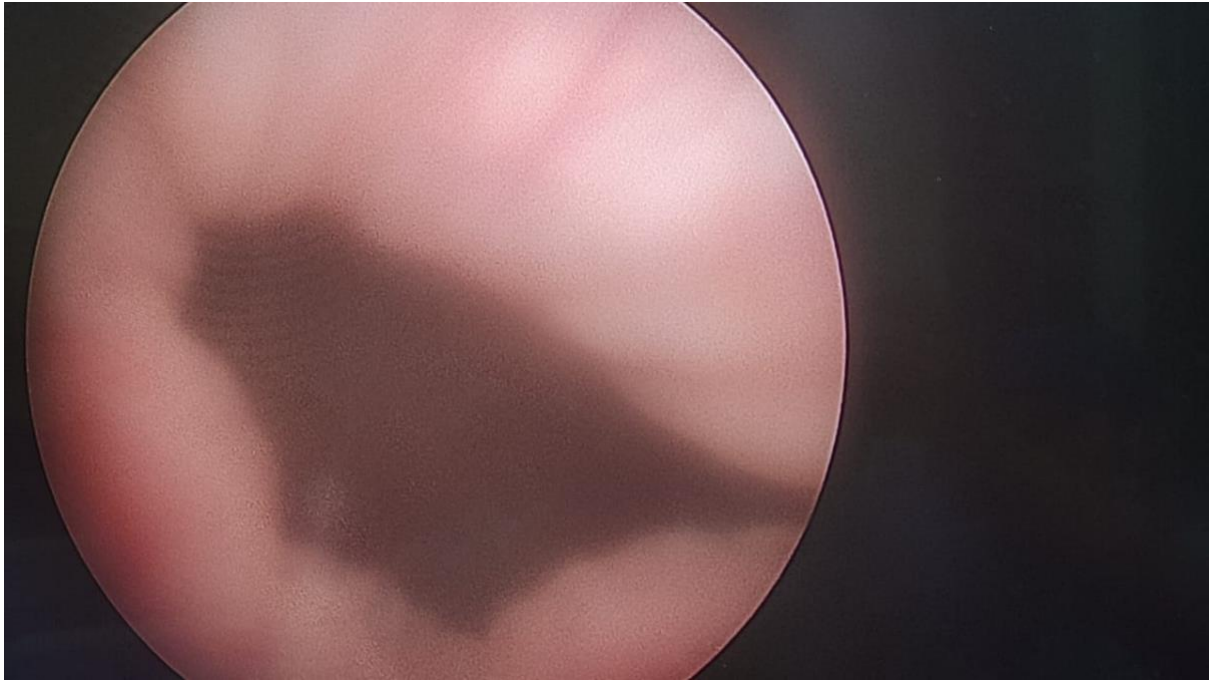


Figure 03- Cystoscopy image showing wide mouth opening of the right sided hutch diverticulum with normal bladder wall inside the diverticulum.

Treatment:

In view of the right sided non-functioning kidney and repeated urinary tract infections, decision was made to go ahead with right sided nephroureterectomy with bladder diverticulectomy with Bladder repair. Through, right sided 11th rib bed cutting incision, right sided nephrectomy with ureteric dissection till the level of common iliac was done and right sided nephrectomy was completed followed by lower midline vertical incision, rest of the right ureter was dissected till the level of the bladder diverticulum. By a combined intravesical and extravesical approach, bladder diverticulectomy was completed. Postoperative course was uneventful. Patient was discharged after 6 days of surgery. Histopathology revealed evidence of scarred right kidney with findings suggestive of pyelonephritis. Patient has been on regular follow up since then now for the last 3 months and no repeat episode of urinary tract infections has been recorded.

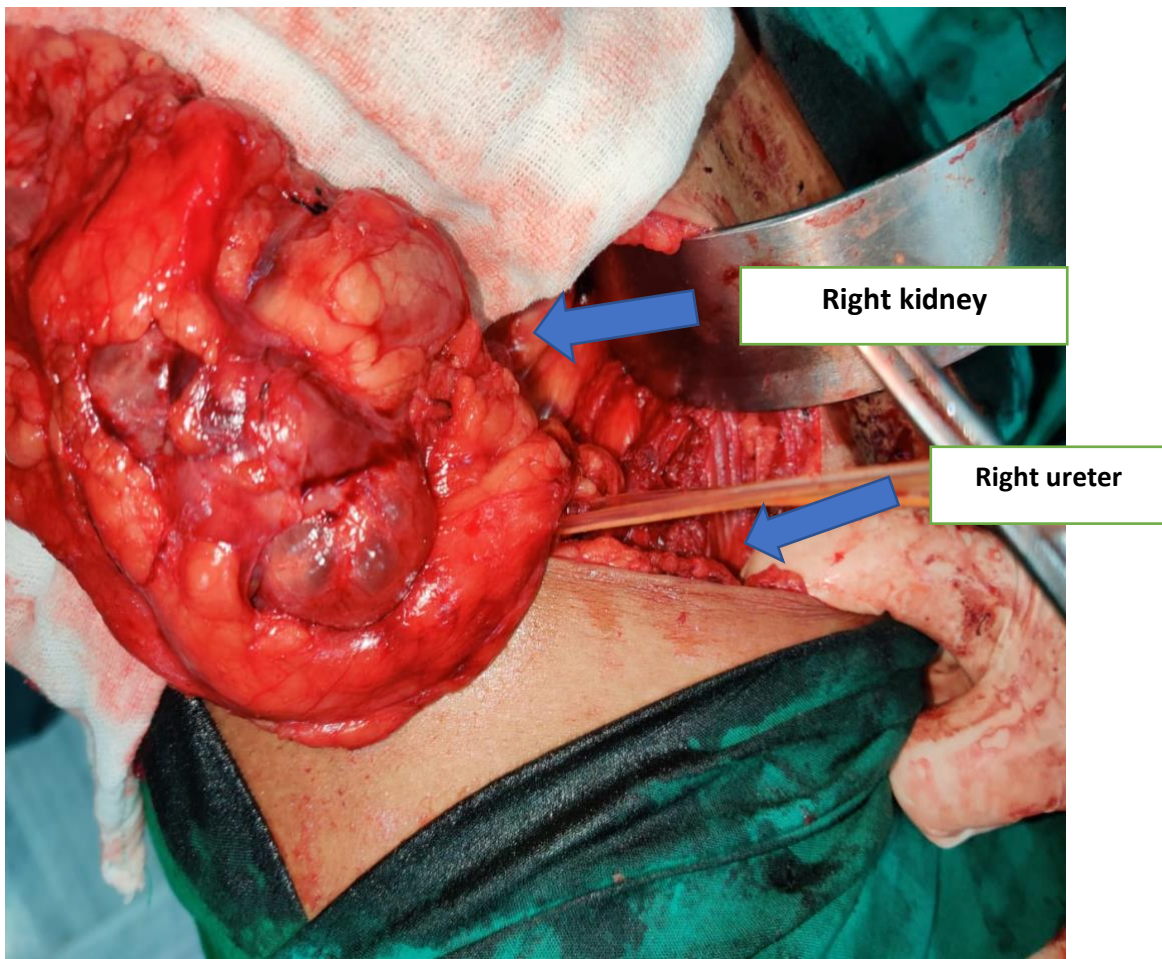


Figure 04- Intraoperative image showing right shrunken small kidney along with the ureter through 11th rib bed cutting incision.

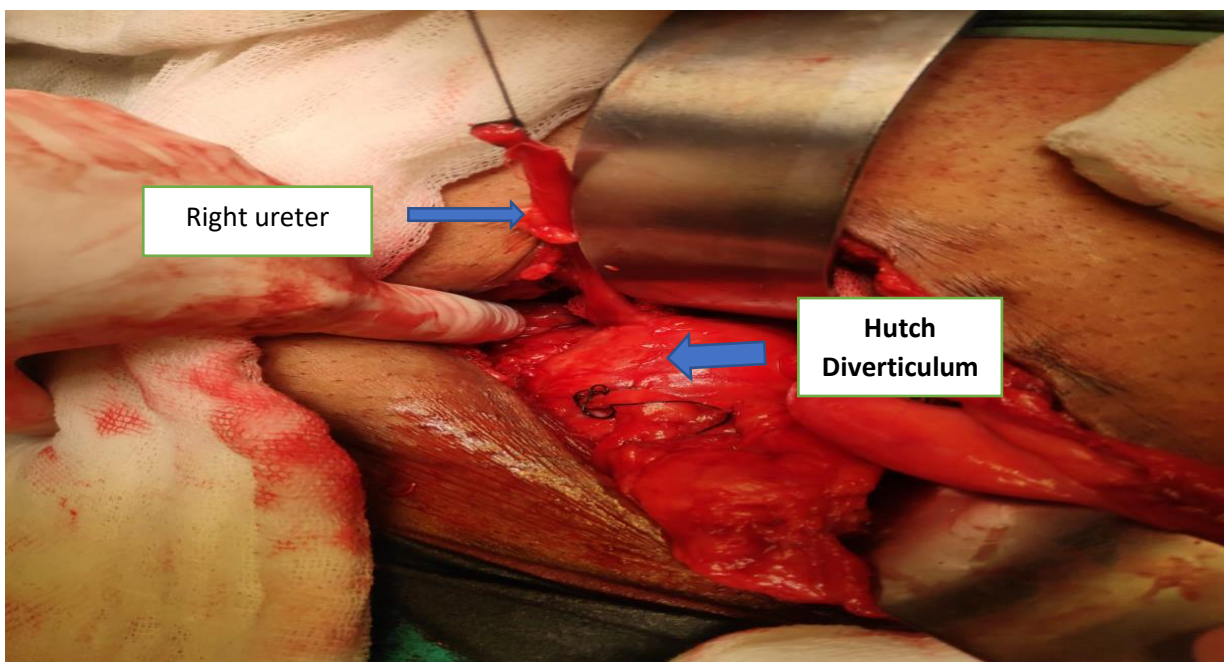


Figure 05- Intraoperative image showing right ureter dissected till the insertion into the Hutch Diverticulum done through a lower midline vertical incision.

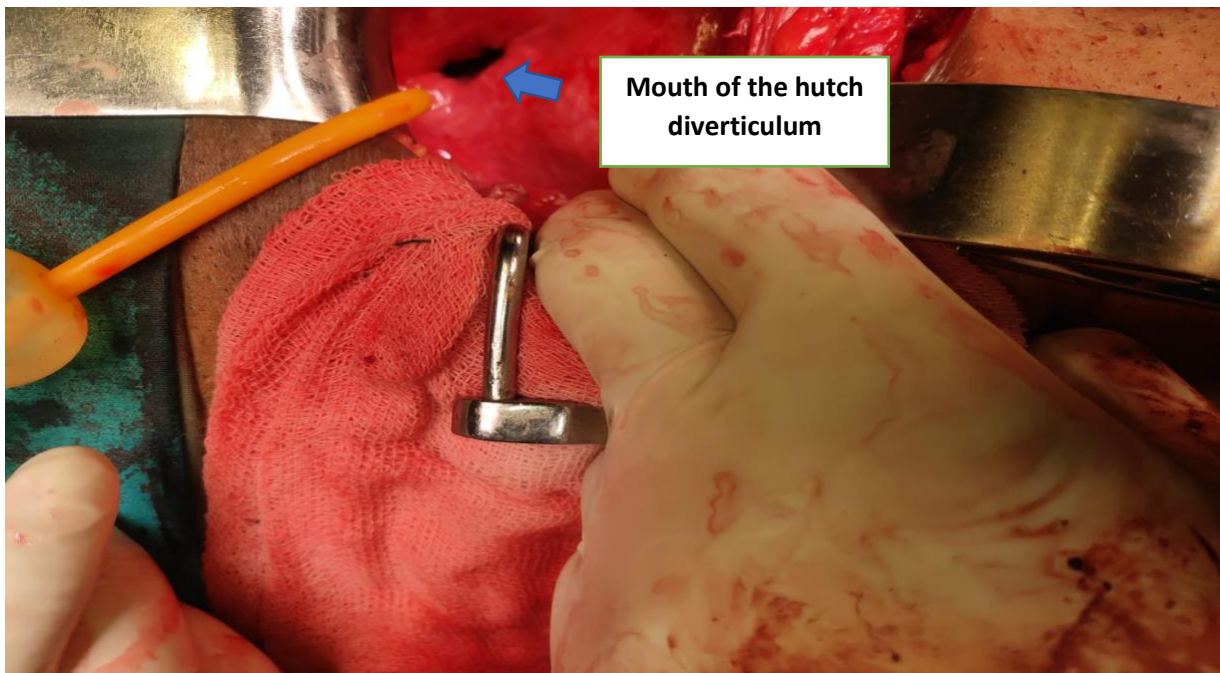

Figure 06- Intraoperative image of intravesical dissection showing mouth of the hutch diverticulum.

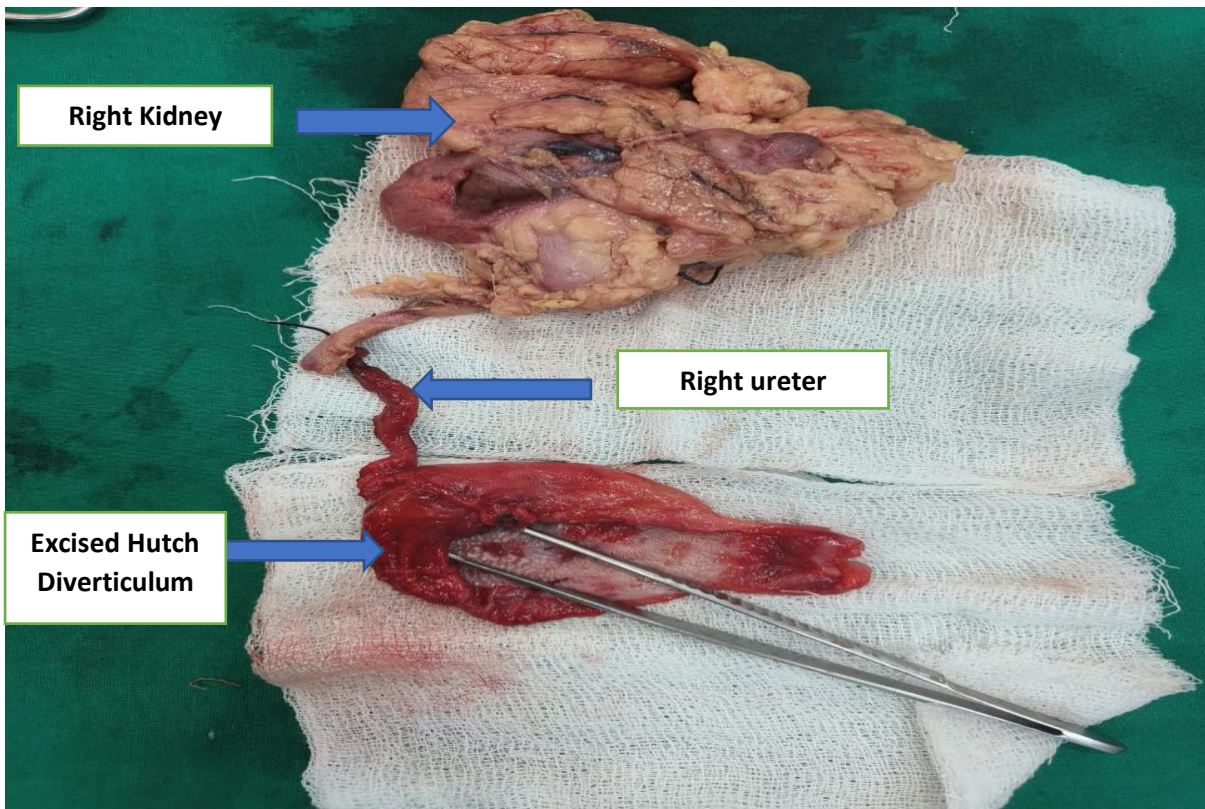


Figure 07- Postoperative image showing the Right nephroureterectomy specimen with excised hutch diverticulum.

Discussion:

The cause of bladder diverticula can be congenital, iatrogenic or most commonly secondary to infravesical obstruction such as posterior urethral valve or due to neurogenic bladder. Paraureteral diverticula or Hutch Diverticula (HD) are located at or adjacent to the ureteral hiatus where Waldeyer's sheath normally seals the potential space between the intravesical ureter and bladder muscle. The ureteral orifice subsequently gets incorporated into the diverticulum as the herniation increases in size. This extravascularisation of the intramural ureter and ensuing ureterovesical incompetence result in vesicoureteric reflux. Some authors support the theory of transient intrauterine bladder outlet obstruction secondary to urethral angulation, a Cowper's gland cyst or posterior urethral membrane² whereas others support the embryological theory of defective incorporation of the mesonephric duct into the bladder at the site of ureter hiatus as the cause of HD.³ Acute urinary retention is an unusual and rare presentation of Congenital Bladder Diverticulum (CBD) most commonly observed in male children. Only two cases have been reported in women^{4,5}. In the largest series, the mean age of presentation was 16.8 months (1–36 months). Of the 53 patients reported, 66.04% (35) were infants, 30.19% (16) were children and 3.77% (2) were observed in adults.⁶ CBD is usually unilateral and rarely bilateral. CBD are also found in patients with connective tissue disorders such as Ehlers-Danlos, Williams-Elfin facies and Menkes syndrome.^{4,7-9} The presentation of acquired diverticulum can be recurrent urinary tract infections, increased post void residual urine volume which in some cases ultimately lead to non-functioning kidney. Ultrasound can be used to detect the diverticula, assess the bladder wall thickness and also helps in assessing upper tract changes. However, if the diverticulum is small and catheter is in situ, then ultrasound will miss the finding. Voiding cystourethrogram (VCUG) is the investigation of choice to diagnose HD. In addition to anteroposterior view, oblique and lateral films need to be obtained so as to demonstrate the diverticula. VCUG will also be able to demonstrate reflux, bladder neck and urethral anatomy in relation to the diverticula. Cystoscopy is invasive but it helps in assessing the size of the diverticulum, intradiverticular pathology such as stone or malignancy, relation of ureteric orifice to the diverticula and the appearance of the bladder neck and urethra. Flexible cystoscopy is useful to assess the lumen in cases where neck of diverticulum is narrow. Small asymptomatic diverticula can be managed conservatively. Giant diverticulum (>1/3rd size of bladder), persistent or recurrent UTI, interference with bladder emptying or outlet obstruction and ureteral obstruction or reflux, presence of intradiverticular disease (tumour or lithiasis) or spontaneous diverticular rupture are absolute indications for surgery.¹⁰ Diverticulectomy may be undertaken by open, transurethral, laparoscopic and robot-assisted approaches. Transurethral method is ideal for small diverticula; it involves incising the diverticulum at the neck or fulgurating the mucosa. The open method may be extravascular, transvesical or a combined approach. An extravascular approach is ideal for larger diverticula and intravesical approach for smaller ones. Open methods carry significant morbidity related to surgery as well as an increased risk of rectal, vesical and urethral injury. The transvesical approach gives additional advantage of incising the bladder neck in cases of bladder neck hypertrophy and treat intradiverticular pathology. However, there is a risk of injuring the pelvic structures and surrounding peritoneum when it is densely adhered to it. The principle of extravascular approach is to dissect close to wall of diverticulum and the muscular defect is meticulously repaired. A combined approach is advisable when there are difficulties in extravascular mobilisation of diverticulae. Ureteric reimplantation is possible in both of the approaches. Lately laparoscopic and robotic-assisted excision has also been proved to be feasible.^{11,12} However, availability, cost and learning curve for the

surgeon become limiting factors. The outcome following intravesical as well as extravesical approaches is excellent.

Conclusion:

This case report highlights the presentation of a paraureteral hutch diverticulum and how it was diagnosed and managed. Also, it stresses the fact that if diagnosed early and treated, the inadvertent result of a non-functioning kidney could be avoided.

References:

1. De Oliveira PS, De Oliveira TR, Martinho D, Lopes T. Hutch bladder diverticulum - unusual cause of adult obstructive uropathy. *Arch Ital Urol Androl.* 2017 Jun 30;89(2):162-163. doi: 10.4081/aiua.2017.2.162. PMID: 28679195.
2. Rovner ES. Bladder and urethral diverticula. In: Kavoussi LR, Novick AC, Partin AW, Peters CA (Ed), *Campbell Walsh Urology*, 9th ed. Philadelphia: WB Saunders Company, 2007; 2361.
3. Singal AK, Chandrasekharam VVSS. Lower tract obstruction secondary to congenital diverticula in infants. *Paediatric Surg Int* 2009; 25:1117–21.
4. Shukla AR, Bellah RA, Canning DA, et al. Giant bladder diverticula causing bladder outlet obstruction in children. *J Urol.*
5. Bogdanos J, Paleodimos I, Korakianitis G, et al. The large bladder diverticulum in children. *J Pediatr Urol* 2005;1:267–72.
6. Bhat A, Bothra R, Bhat MP, et al. Congenital bladder diverticula presenting as bladder outlet obstruction in infants and children. *J Pediatr Urol* 2012; 8:348–53.
7. Burrows NP, Monk BE, Harrison JB, et al. Giant bladder diverticulum in Ehlers-Danlos syndrome type I causing outflow obstruction. *Clin Exp Dermatol* 1998; 23:109–12.
8. Harcke HT Jr, Capitanio MA, Grover WD, et al. Bladder diverticula and menkes' syndrome. *Radiology* 1977; 124:459–61.
9. Babbit DP, Dobbs J, Boedecker RA. Multiple bladder diverticula in Williams "Elfin-Facies" syndrome. *Pediatr Radiol* 1979; 8:29–31.
10. Verghese M, Belman AB. Urinary retention secondary to congenital bladder diverticula in infants. *J Urol* 1984; 132:1186–8.
11. Kok KY, Seneviratne HS, Chua HB, et al. Laparoscopic excision of congenital bladder diverticulum in a child. *Surg Endosc* 2000; 14:501.
12. Christman MS, Casale P. Robot-assisted bladder diverticulectomy in paediatric population. *J Endourol* 2012; 26:1296–300.

